

Functional significance of heat shock protein (Hsp) 25 during pulpal regeneration after cavity preparation and tooth replantation in rat molars

Ohshima H^{1*}, Nakakura-Ohshima K²

Division of Anatomy and Cell Biology of the Hard Tissue, Department of Tissue Regeneration and Reconstruction, Niigata University Graduate School of Medical and Dental Sciences¹

Polyclinic Intensive Oral Care Unit, Niigata University Dental Hospital²

2-5274 Gakkochi-dori, Niigata 951-8514, Japan

E-mail (H Ohshima): histoman@dent.niigata-u.ac.jp

Abstract

The regeneration process of the odontoblast cell layer incident to tooth injury has not been fully understood. The purpose of the present study was to clarify the fate and regeneration process of odontoblasts during the pulpal healing following cavity preparation and tooth replantation in rat molars by immunocytochemistry for heat shock protein (Hsp) 25. In untreated control teeth, intense Hsp 25-immunoreactivity was found in the cell bodies of odontoblasts. Cavity preparation caused the destruction of the odontoblast layer to form an edematous lesion, and some damaged odontoblasts without apparent cytoplasmic processes retained the immunoreactivity for Hsp 25, suggesting the survival of a part of the odontoblasts against artificial external stimuli. By postoperative 72 hours, newly-differentiated odontoblasts with Hsp 25-immunoreactivity were arranged at the pulp-dentin border. On the other hand, tooth replantation caused loss of Hsp 25-immunoreactions in the coronal dental pulp during postoperative days 1-3. At postoperative day 5, newly differentiated odontoblasts at the pulp-dentin border became immunopositive for Hsp 25. These findings indicate that the time course of changes in the expression of Hsp 25-immunoreactivity reflects the degeneration/regeneration process of odontoblasts.

Introduction

The tooth is often exposed to dental caries, attrition, abrasion and restorative procedures such as cavity preparation to cause injury to dental pulp. The procedure of cavity preparation induces destructive changes in odontoblasts at the affected site as well as an acute inflammatory reaction (Ohshima, 1990). If the odontoblasts survive, they are capable of

depositing further reactionary dentin. If not, pulpal mesenchymal cells take the place of the degenerated odontoblasts to differentiate into new odontoblasts resulting in the formation of reparative dentin (Smith, 2002). On the other hand, tooth replantation, defined as a therapeutic method in which an extracted tooth is replaced into its original alveolar socket, has come to be utilized in clinical dentistry. This procedure causes interruption of the nerve and

vascular supply to the dental pulp, and tissue responses can be divided into at least two types: reparative dentin and bone-like tissue formation in the regenerated pulp tissue (Shimizu et al., 2000). However, the regeneration process of the odontoblast cell layer incident to tooth injury has not been fully understood, one of reasons being the lack of any reliable marker substance for differentiation of odontoblasts until recently.

Heat shock protein (Hsp) 25, the family of low molecular weight Hsps, is expressed in normal various cells as well as under stressful conditions, although it was first discovered under the latter conditions (for reviews, see Ciocca, 1993; Arrigo and Prévaille, 1999). This protein has been reported to possess diverse functions such as molecular chaperones, or modulating actin dynamics to protect cell motility and shape, a specific inhibitor of apoptosis and promoter of cell survival. In addition to stressful and normal conditions, the transient expression of Hsp 25 has been shown during cellular development and differentiation (Arrigo and Prévaille, 1999). Our recent studies have demonstrated a stage-specific expression pattern of Hsp 25-immunoreactivity in the odontoblasts under normal (Ohshima et al., 2000, 2002a) and experimental conditions (Ohshima et al., 2001a, b, 2002b), suggesting that this protein is a useful marker for the differentiation of odontoblasts during the pulpal healing process after tooth injury. The functional roles of Hsp 25-immunoreactions in the process of pulpal regeneration after cavity preparation and tooth replantation are discussed from our recent experimental data.

Materials and Methods

All experiments were performed following the Guidelines of the Niigata University Intramural Animal Use and Care Committee.

Wistar rats, 4 weeks and 100 days old, were used in this study for cavity preparation, and tooth replantation respectively. For cavity preparation, a groove-shaped cavity was prepared on the mesial surface of the upper right first molar by use of an air turbine under anesthesia. The cavity was left without any further treatment. For tooth replantation, the upper right first molar was extracted with a pair of Howe's pliers and then was immediately repositioned into the original socket under anesthesia. The replanted tooth was left without any further treatment. In both experiments, the upper left first molar of the same animal was used as a control.

Materials were collected at intervals of 0 – 72 hours after cavity preparation, and 1 – 14 days after replantation. At each stage, the animals were anesthetized and transcardially perfused with physiological saline followed with 4% paraformaldehyde in a 0.1 M phosphate buffer. The maxillae were removed *en bloc* and immersed in the same fixative. Following decalcification in a 5% ethylenediaminetetraacetic acid disodium salt (EDTA-2Na) solution for 4 weeks at 4 °C, the tissue blocks were equilibrated in a 30% sucrose solution for cryoprotection. The specimens were cut sagittally at a thickness of about 50 µm with a freezing microtome, collected into cold phosphate buffered saline (PBS), and treated as free-floating sections.

For the immunohistochemistry, frozen sections were processed for the avidin-biotin peroxidase complex (ABC) method using a polyclonal antibody to Hsp 25 (diluted 1:5000; StressGen Biotechnologies Corp., Victoria, BC, Canada). Detailed protocol for immunohistochemical procedure and further characterization of the primary antibodies has been reported elsewhere (Ohshima et al., 2000).

Immunohistochemical controls were performed by: 1) replacing the primary antibodies with non-immune serum or PBS; 2) omitting the anti-rabbit IgG or the ABC complex. These immunostained sections did not contain any specific immunoreaction.

Results and Discussion

In the present immunocytochemical study, both cavity preparation and tooth replantation caused drastic time-related alterations in Hsp 25 expression in the odontoblasts in degeneration/regeneration process in rat molars.

In untreated teeth, the immunoreaction within odontoblasts comprised the cell bodies and the bottom of their processes. No immunonegative odontoblast was found in the control teeth of 100-day-old rats. At postnatal 4 weeks, on the other hand, the odontoblasts showed intense Hsp 25-immunoreactivity in the coronal dental pulp, but little or no immunoreactivity in the root and floor pulp. These findings suggest that the expression of Hsp 25-immunoreactivity reflects the status of differentiation for odontoblasts.

Cavity preparation rapidly induced an exudative lesion between the predentin and

impaired odontoblast layer. The odontoblasts under the prepared cavity suffered severe damage and a diminished Hsp 25-immunoreaction. The impaired odontoblasts without an Hsp 25-immunoreaction and the Hsp 25-positive cells without apparent cell processes were intermingled in the damaged odontoblast cell layer. Intense Hsp 25-positive cells were situated apart from the predentin and remained until 24 hours after cavity preparation. The pulp-dentin border lost the immunoreactivity for Hsp 25, in spite of the occurrence of some cells there by 12 hours. After 24 hours, a weak Hsp 25-immunoreactivity was found in some mesenchymal cells at the area apart from the predentin. By 72 hours, the Hsp 25-immunoreactive plump cells, newly-differentiated odontoblasts, lined up in the proper odontoblast layer. Figure summarizes the spatiotemporal relationship between Hsp 25-positive odontoblasts and immunocompetent cells at the pulp-dentin border following cavity preparation on the basis of the data obtained from our recent study (Ohshima et al., 2002b).

There has been controversy over the fate of the damaged odontoblasts after cavity preparation. The alterations in the expression of Hsp 25-immunoreactivity in the odontoblasts as shown in this study seems to well reflect the status of their degeneration/regeneration process; the injured odontoblasts at the pulp-dentin border lost the Hsp 25-immunoreactivity at postoperative 6 hours, but they retained their immunoreaction in the area apart from the predentin 24 hours after the cavity preparation.

Tooth replantation caused a complete disappearance of the Hsp 25-immunoreactivity in the odontoblasts throughout the pulp. After 5 days, plump cells with several fine processes and clear nucleoli, newly differentiated odontoblasts, aligned along the pulp-dentin border and showed an intense Hsp 25-immunoreactivity. Most odontoblasts in the coronal and root pulp became immunoreactive for Hsp 25 by postoperative day 14 when the

reparative dentin formation was progressing in all areas. In the case of bone-like tissue formation in the pulp space, on the other hand, no Hsp 25-immunoreactive odontoblasts were recognized in the pulp-dentin border. Thus, the alignment of Hsp 25-immunopositive odontoblasts along the pulp-dentin border indicates a decisive factor for inducing the reparative dentin formation after tooth replantation.

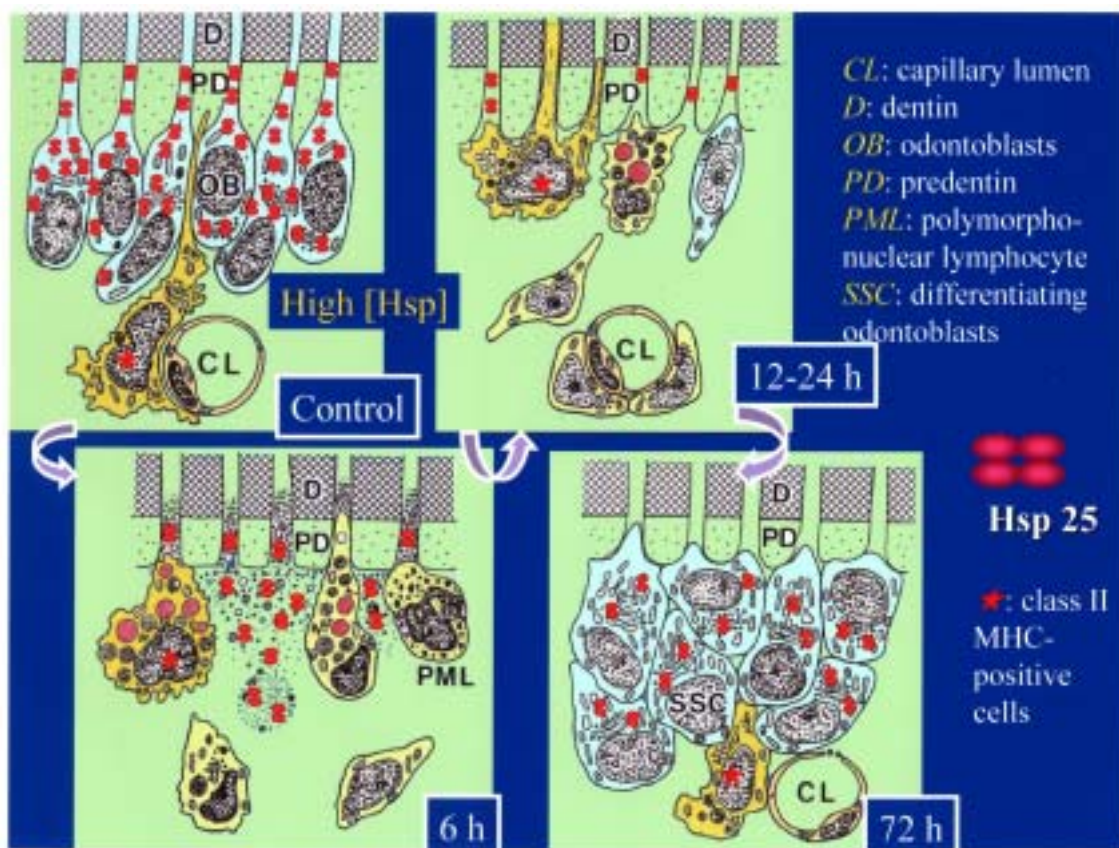


Figure. A schematic diagram summarizing the spatiotemporal relationship between Hsp 25-immunopositive cells and class II MHC-positive cells following cavity preparation (Modified from Ohshima et al., 2002b). In a control tooth, a class II MHC-positive dendritic cell is located beneath the Hsp 25-immunoreactive odontoblast cell layer. Class II MHC-positive and negative macrophages gather at the pulp-dentin border 6 hours after cavity preparation. A class II MHC-positive dendritic cell appears along the pulp-dentin border and extends its processes into the exposed dentinal tubules during postoperative 12-24 hours. By postoperative 72 hours, a class II MHC-positive dendritic cell moves beneath newly-differentiated odontoblasts with Hsp 25-immunoreactivity, which locate at the pulp-dentin border.

References

- Arrigo, A.P., and Prévile, X. (1999) Role of Hsp 27 and related proteins. In: Handbook of experimental pharmacology, Vol. 136. Stress proteins, Chap. 5. D. S. Latchman, ed. Springer, Berlin – New York, pp. 101-132.
- Ciocca, D.R., Oesterreich, S., Chamness, G.C., McGuire, W.L., and Fuqua, S.A.W. (1993) Biological and clinical implications of heat shock protein 27,000 (Hsp27): a review. *J. Natl. Cancer Inst.*, 85:1558-1570.
- Ohshima, H. (1990) Ultrastructural changes in odontoblasts and pulp capillaries following cavity preparation in rat molars. *Arch. Histol. Cytol.*, 53:423-438.
- Ohshima, H., Ajima, H., Kawano, Y., Nozawa-Inoue, K., Wakisaka, S., and Maeda, T. (2000) Transient expression of heat shock protein (Hsp) 25 in the dental pulp and enamel organ during odontogenesis in the rat incisor. *Arch. Histol. Cytol.*, 63:381-395.
- Ohshima, H., Nakakura-Ohshima, K., Yamamoto, H., and Maeda, T. (2001a) Alteration in the expression of heat shock protein (Hsp) 25-immunoreactivity in the dental pulp of rat molars following tooth replantation. *Arch. Histol. Cytol.*, 64:425-437.
- Ohshima, H., Nakakura-Ohshima, K., Yamamoto, H., and Maeda, T. (2001b) Responses of odontoblasts to cavity preparation in rat molars as demonstrated by immunocytochemistry. *Arch. Histol. Cytol.*, 64:493-501.
- Ohshima, H., Nakakura-Ohshima, K., and Maeda, T. (2002a) Expression of heat-shock protein 25 immunoreactivity in the dental pulp and enamel organ during odontogenesis in the rat molar. *Connect. Tissue Res.*, 43:220-223.
- Ohshima H., Nakakura-Ohshima K., Takeuchi K., Hoshino M., Takano Y., and Maeda T. (2002b) Pulpal regeneration after cavity preparation, with special reference to close spatio-relationships between odontoblasts and immunocompetent cells. *Microsc. Res. Tech.* in press
- Shimizu, A., Nakakura-Ohshima, K., Noda, T., Maeda, T., and Ohshima, H. (2000) Responses of immunocompetent cells in the dental pulp to replantation during the regeneration process in rat molars. *Cell Tissue Res.*, 302:221-233.
- Smith A. J. (2002) Dentin formation and repair. In: Seltzer and Bender's dental pulp. K. M. Hargreaves and H. E. Goodis, eds. Quintessence Publishing Co., Inc., Chicago – Berlin – Tokyo – London – Paris – Milan – Barcelona – Istanbul – São Paulo – New Delhi – Moscow – Prague – Warsaw, pp. 41-62.

Acknowledgements

This work was supported by a Grant for Promotion of Niigata University Research Projects and by Grants-in-Aid for Scientific Research (to promote 2001-Multidisciplinary Research Projects in 2001-2005; nos. 12671765 and 14571727 to H.O. and 13672141 to K.N.-O.) from the Ministry of Education, Culture, Sports, Science, and Technology, Japan