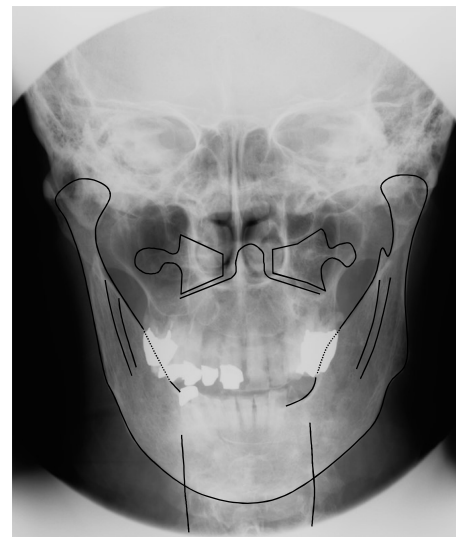
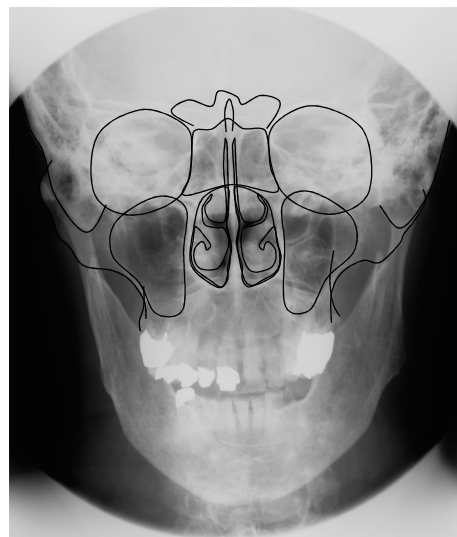
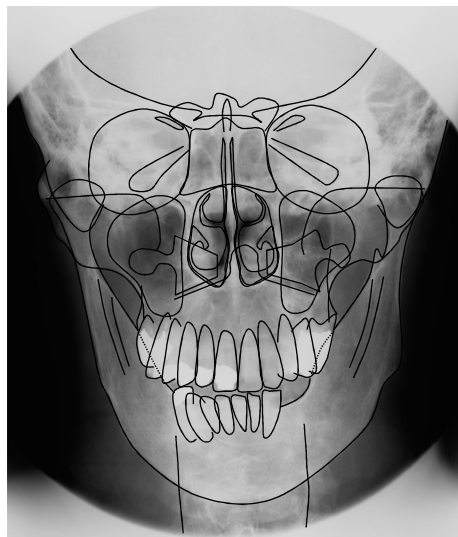
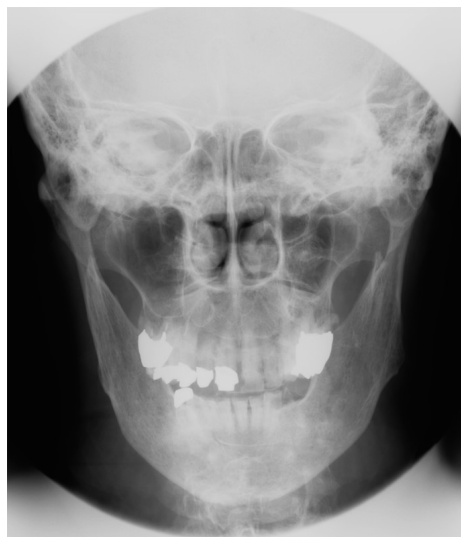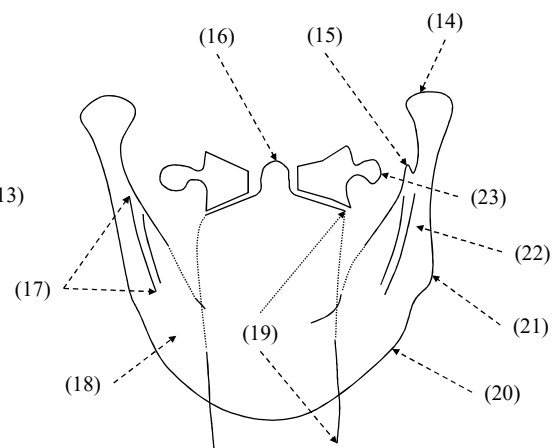
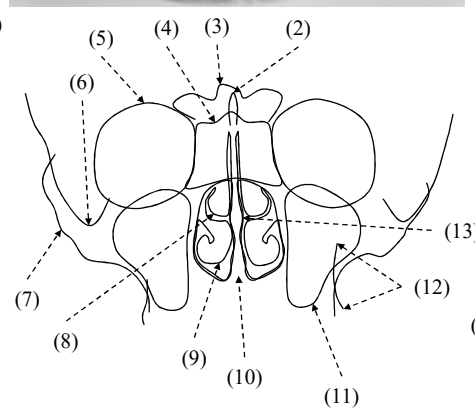
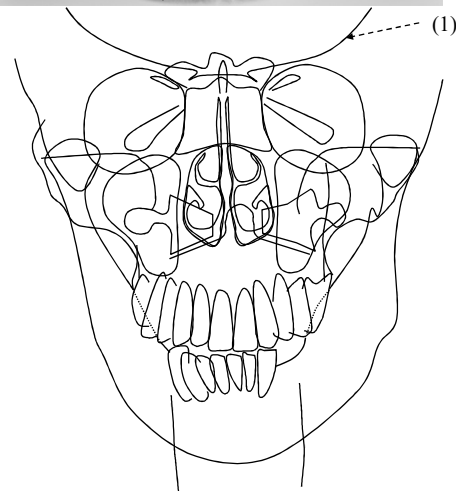


後頭・前頭方向撮影(P→A)



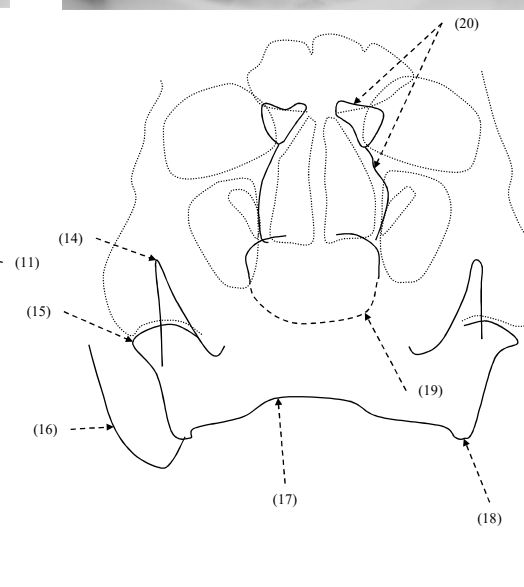
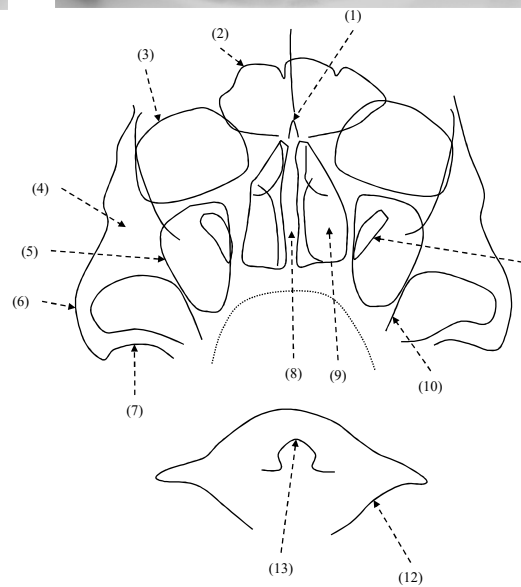
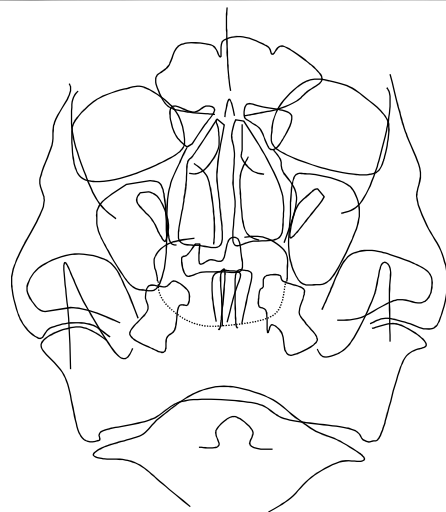
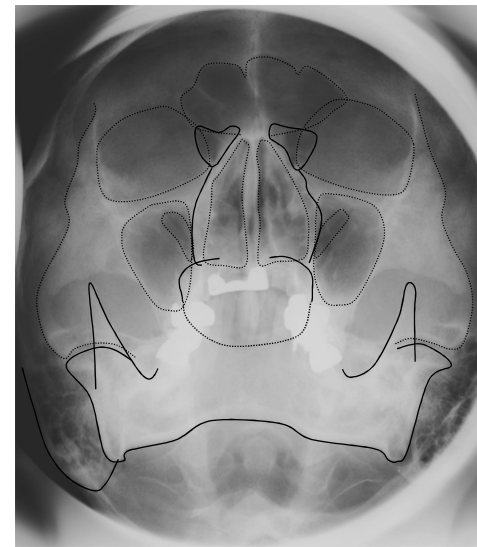
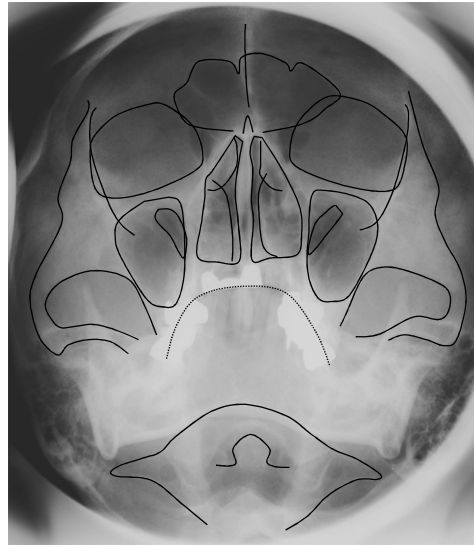
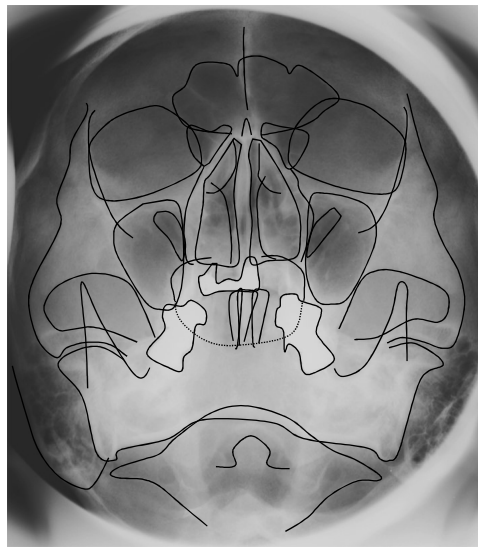
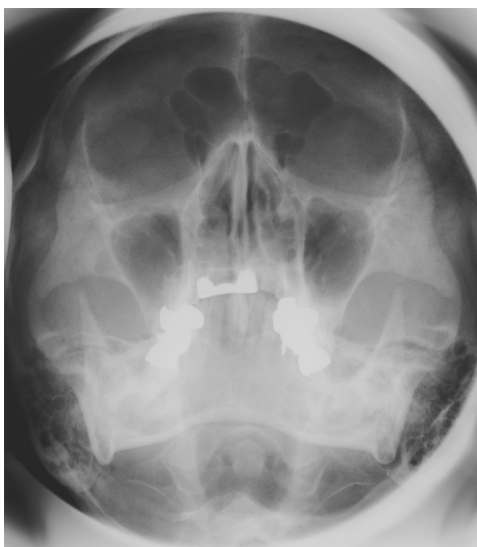
- (1)
- (2)
- (3)
- (4)
- (5)
- (6)
- (7)
- (8)
- (9)
- (10)
- (11)
- (12)
- (13)
- (14)
- (15)



- (16)
- (17)
- (18)
- (19)
- (20)

- (21)
- (22)
- (23)

Waters'法



- (1)
- (2)
- (3)
- (4)
- (5)
- (6)
- (7)
- (8)
- (9)
- (10)
- (11)
- (12)
- (13)
- (14)
- (15)

- (16)
- (17)
- (18)
- (19)
- (20)

後頭・前頭方向撮影(P→A)

- (1) 頭蓋底 skull base
- (2) 鷄冠 crista galli
- (3) 前頭洞 frontal sinus
- (4) 篩骨蜂巢 ethmoid cells
- (5) 眼窩 orbit
- (6) 乳様突起 mastoid process
- (7) 頬骨弓 zygomatic arch
- (8) 中鼻甲介 middle turbinate
- (9) 下鼻甲介 inferior turbinate
- (10) 前鼻棘 anterior nasal spine
- (11) 上顎洞 maxillary sinus
- (12) TM line (tuber-maxillary line)
- (13) 鼻中隔 nasal septum
- (14) 下顎頭 condylar head
- (15) 筋突起 coronoid process
- (16) 齒突起(C2) dens
- (17) 下顎管 mandibular canal
- (18) 下顎体 mandibular body
- (19) 頸椎 cervical vertebra
- (20) 下顎骨下縁 inferior border of mandible
- (21) 下顎角 mandibular angle
- (22) 下顎枝 mandibular ramus
- (23) 環椎横突起 transverse process of C1

Waters'法

- (1) 鷄冠 crista galli
- (2) 前頭洞 frontal sinus
- (3) 眼窩 orbit
- (4) 頬骨 zygomatic bone
- (5) 上顎洞 maxillary sinus
- (6) 頬骨弓 zygomatic arch
- (7) 下顎窩 mandibular fossa
- (8) 鼻中隔 nasal septum
- (9) 下鼻甲介 inferior turbinate
- (10) 頬骨下稜 zygomaticoalveolar line
- (11) 上眼窩裂
- (12) 環椎(C1)
- (13) 齒突起(C2) dens
- (14) 筋突起 coronoid process
- (15) 下顎頭 condylar head
- (16) 乳様突起 mastoid process
- (17) 下顎骨下縁 inferior border of mandible
- (18) 下顎角 mandibular angle
- (19) 蝶形骨洞 sphenoid sinus
- (20) 篩骨蜂巢 ethmoid cells